

KSHV/HHV-8 and HIV infection in Kaposi's sarcoma development

*Pawan Pyakurel¹, Amos. R. Mwakigonja^{1/2}, Fatemeh Pak¹, Ephata Kaaya^{1/2}, Peter Biberfeld¹,

¹Immunopathology Lab., Department of Pathology and Oncology, Karolinska Institute/Hospital, S-171 76 Stockholm, Sweden, ²Muhimbili University College of Health Sciences, P. O. Box 65023, Dar-Es-Salaam, Tanzania,

*Correspondence: Pawan Pyakurel, Immunopathology Laboratory, M9:00, Karolinska Institute/Hospital, S171-76, Stockholm, Sweden. Tel: 46-8-5177 4523. Fax: 46-8-345820. E-mail: pawan.pyakurel@ki.se

Supported by Swedish International Development Agency (Sida), Department of Research Cooperation (SAREC) and by Swedish Cancer Society, Cancer Society of Stockholm, and Karolinska Institutet research fund.

Kaposi's sarcoma

Kaposi's sarcoma first described by Moritz Kaposi in 1872 as "idiopathic multiple pigmented sarcomas of the skin" [1] is an angioproliferative, tumour-like lesion usually developing in the skin [2], and eventually disseminating to multiple cutaneous sites, viscera and lymph nodes. Previously a rare disease, it is now a global health care and clinical problem because of its association with the HIV pandemic [3] and other immunosuppressed states[4].

Four clinically different KS forms are now recognized [5]:

- a) Classical or sporadic KS (CKS), originally described [1] as a slow growing, indolent tumor mostly developing in the extremities of elderly males of eastern and Mediterranean Europe.
- b) Endemic KS (EKS), predominant in eastern and central sub-Saharan Africa before the AIDS epidemic and clinically similar to CKS, but also seen in a more fulminant and fatal form in children. The childhood EKS is often lymphoglandular with or without skin involvement.
- c) Acquired immunodeficiency syndrome (AIDS)-associated KS (AKS), the most frequent tumor of human immunodeficiency virus type I (HIV-1) infection and the most aggressive and rapidly growing form of KS in AIDS, with early dissemination in the skin and viscera.
- d) Iatrogenic KS (IKS), seen in drug related immunosuppressed patients, e.g. transplant patients, emphasizing the importance of immune disturbance as a co-factor in the pathogenesis of IKS and AKS, and possibly also EKS.

In spite of the clear clinical differences the histopathology of the various KS forms is essentially the same, with characteristic changes related to stage in the development of the KS tumor[6].

The epidemiology of AKS led to the discovery of a novel herpes virus [7], which subsequently was shown to be associated with all clinico-epidemiological forms of KS [8]. The virus was rapidly characterised as a KS associated herpes virus (KSHV) and classified as human herpes virus type 8 (HHV-8). It was soon recognized to be associated with some rare types of lymphomas in AIDS patients, namely primary effusion lymphoma or body-cavity-based-lymphoma (PEL/BCBL) and Castleman's disease (MCD)[9].

Human herpesvirus type 8 (HHV-8)

Human herpesvirus 8 or Kaposi's sarcoma associated herpesvirus (HHV-8/KSHV) was recognized to be a novel gamma-2 herpesvirus of the rhadinovirus genus closely related to the human gamma -1 herpesvirus, Epstein-Barr virus (EBV) [10].

A number of viral glycoproteins have been characterized shown to bind to cell surface heparan sulfate [11] and the cell receptor integrin $\alpha 3\beta 1$, respectively, thereby mediating virus

entry through endocytosis [12]. In the KS lesion HHV-8 is predominantly found in the so called tumor spindle (SC) cells in KS but was also in some lymphocytes, monocytes and keratinocytes [13]. The virus replicates predominantly in a latent form as closed circular episomal DNA [14] within the nucleus of KS tumor cells (SC), B cells of MCD and other infected mononuclear cells [15] or in lytic form. It has been shown that the episomal viral DNA is tethered to metaphase chromosomes and copied in tandem with host cell DNA during cell division [16]. Latent viral specific genes well demonstrated in infected KS SC are the latent nuclear antigen (LANA-1), viral cyclin (v-cyclin), v-FLIP and kaposin a small membrane protein, which are all adjacent in the genome [16]. Lytic virus expression is most frequent in MCD, moderate in KS and relatively rare in PEL cells. Common viral genes found during lytic expression include K1 transmembrane protein, v-GCR, v-IRF, v-IL-6 and v-MIP [15].

LANA-1

The latency associated nuclear antigen type 1 (LANA-1) protein is well expressed and highly immunogenic, latent nuclear antigen of HHV-8 considered important in the generation and maintenance of HHV-8 associated malignancies [17] by its function in cell cycle regulation [18] of apoptosis [19].

The LANA-1 antigen is well detectable by immunohistochemistry also in routinely formalin fixed paraffin embedded biopsies. It is expressed by most SC in both early and late stage lesions of all different clinical KS forms (AKS, EKS, CKS and IKS) [8, 20] and therefore used as a diagnostic marker in suspected HHV-8 related lesions and also for serology of LANA-1 antibodies in patients by immunocytochemistry that gives a characteristic speckled nuclear staining on HHV-8 infected BCBL cells. Several studies have shown an increase in LANA-1 positive cells during progression of KS lesions [21, 22] allowing quantification and phenotyping of these cells in KS lesions.

Pathogenesis of KS

The pathogenesis of KS is still unclear and appears complex, involving various mechanisms dependent on viral and cellular factors related to inflammation, angiogenesis factors as endothelial growth factors (β -FGF, PDGF, VEGF) including HIV-Tat, cell proliferation and anti-apoptosis (vBCL2) [2, 13, 23, 24]. Characteristic for HHV-8 is the high homology of

several viral and cellular genes suggesting viral genes were pirated from host chromosomes during viral evolution. Some of these genes are involved in down modulating the host immune responsiveness to target, infect cells and modulate cell proliferation, cell differentiation and angiogenesis [13], including genes as vBcl-2, vIL-8R, vMIPs, vIL-6, and the D type viral cyclin

The HHV-8 infected cells escape immune response targeting by down regulation of surface MHC mediated by two transmembrane proteins, MIR1 and MIR2 [25] (Fig 1), which promote MHC endocytosis, and lysosomal degradation (Fig 1). Downregulation of MHC I and its accessory immune receptors poses the risk of initiating a natural killer (NK) cell response by initiating apoptosis through Fas (CD95/Apo-1) in cells lacking appropriate MHC I expression. However, HHV-8 can inhibit NK-mediated killing through expression of the anti apoptotic v-FLICE-inhibitory proteins (v-FLIPs) [25]. V-FLIP which acts as a dominant inhibitor of receptor-activated apoptosis by binding to Fas-associated death domain protein and caspase 8 (FLICE) [26]. This prevents activated caspase recruitment into the death-inducing signaling complex (Fig 1).

HHV-8 v-FLIP shares with c-FLIPs the ability to activate NF- κ B [25] which is essential for the growth and survival of the cell. Our studies on KS biopsies have shown that apoptosis clearly decreases during development of early to late nodular KS lesions [27], and that the expression of anti-apoptotic v-FLIP and cellular Bcl-2 increase from early to late stage KS lesions, [27, 28]. Thus viral exploitation of these two anti-apoptotic pathways contributes to the tumor-like growth and progression of the KS lesion.

V-cyclin binds with cyclin dependent kinases (CDK6), which complex phosphorylates pRb, releasing a transcription factor (E2F), which activates the transcription of S-phase genes (Fig 1). However, unlike cellular cyclin, vCyclin-CDK6 complexes are resistant to CDK inhibitory proteins, which may lead to unregulated cell cycle progression and transformation and thereby promote tumor development [29].

Kaposin, the latency gene represents a potential viral oncogene and is characterized as a transforming gene [30], although little is known about its role in deregulating cell signalling [31]. It is present in three (A, B, C) isoforms [32] of which Kaposin B is expressed by all HHV-8 infected cells and can activate the p38–MK2 pathway [33] (Fig 1) and block the degradation of the messenger RNAs transcribing various cytokines necessary for cell survival, hence increasing their translation [33]. The Kaposin gene also encodes MicroRNAs (miRNA), which can regulate expression of genes by binding to the complementary messenger RNAs [34]. Two HHV-8 miRNAs are located in the kaposin gene [34], which is expressed by SC at

all KS stages [35] and may contribute to tumorigenic transformation of infected cells [30], and therefore be of therapeutic interest [34].

HHV-8 also encodes a G-protein-coupled receptor (vGCR) homolog to the human angiogenic, chemokine interleukin-8 receptor (IL-8R) [36] (Fig 1). Angiogenic responses induced by vGCR are mediated by upregulation of vascular endothelial growth factor (VEGF) [37]. The constitutive activity of vGCR could therefore have a role for VEGF expression by SC during the development of early stage KS lesions [38]. Furthermore the vGCR dependent expression of autocrine and paracrine growth factors (bFGF, VEGF,) promotes the angiogenesis and edema [23, 39] seen in KS patients. It was also shown [40] that viral envelop glycoprotein gB can activate the VEGFR-3 receptor and trigger receptor signalling on the surface of microvascular endothelial cells, thereby modulating cell migration and proliferation. VEGFR-3 expression and activation may also enhance HHV-8 infection and participate in HHV-8 mediated transformation [40] and thereby appears to be an important factor in the pathogenesis of Kaposi's sarcoma.

Histogenesis of KS

The histopathology of KS is characterized by an early infiltration of mononuclear inflammatory cells, formation of small, irregular, endothelial lined slits around new blood vessels (angiogenesis) and extravasation of erythrocytes [2] with accumulation of hemosiderin pigments. KS at early stages appears to reflect a predominantly reactive cell proliferation of polyclonal nature that may regress, but usually progresses to a nodular possibly clonal tumor [2, 41]. Pathognomonic for KS development from early patch/plaque to late nodular tumor lesions is the increased appearance of bundles of morphological spindle cells (SC) expressing CD34 (hematopoietic stem cell and vascular endothelial marker). At the late nodular KS stage there is less inflammatory cell infiltration, mostly around the borders of the dense, nodular accumulation of SC bundles which skin lesions later may ulcerate. Unlike typical metastatic cancers, KS often appears early as a multicentric tumour, with each lesion arising de novo by a localized small patch and of SC [42].

Most SC are positive for CD34 and LANA but a considerable number of CD34+ SC are LANA- at all AKS/EKS stages [21, 22]. This apparent heterogeneity in viral permissiveness of CD34+ SC seems less compatible with a clonal CD34+ SC proliferation and virus transfer but appears to indicate that also non-infected CD34⁺ SC are continuously recruited from progenitor cells and locally triggered to develop permissiveness to HHV-8 infection [21, 22]. Furthermore cells belonging to the non-cycling SC (Ki67-) population showed a clear

increase during development from patch/plaque (median 13.5%) to nodular stage (median 40.3%) [21], also supporting the concept of continuous recruitment of CD34+ cells to the lesion. KS spindle-like cells have been shown to develop in cultures of peripheral blood of HIV infected patients with KS or at high risk for developing KS [43]. Furthermore recent studies show that endothelial cells or their precursors residing in donor kidneys may contribute to post-renal transplant KS indicated by the finding that KS SC in the female recipient kidney had a male (donor) karyotype and that KS SC expressed the donor HLA antigen [44]. These findings appear to indicate that KS SC and/or their progenitors can be recruited during development of KS lesion.

Characteristic spindle cells (SC) express various “mixed” (LEC and VEC) endothelial phenotypic cell markers possibly representing hybrid phenotypes of endothelial cells at different maturation stages. It has been recurrently debated whether SC are vascular (VEC) or lymphatic (LEC) in origin or derive from mesenchymal progenitor cells [45-47], although most studies by immunohistochemistry have revealed that SC express lymphatic markers, such as D2-40 [48], LYVE-1 [45] and VEGFR-3 [46]. Also studies by gene expression microarray show that KS neoplastic cells are closely related to lymphatic endothelial cells (LEC) but coexpressing some blood vascular endothelial cell (VEC) markers [49]. Furthermore HHV-8 can infect both LEC and VEC in vitro and infected LEC had a higher HHV-8 genome copy number than VEC[49]. In-vitro infection of CD34+ human dermal microvascular endothelial cells (HDMEC) with HHV-8 resulted in the upregulation of LEC markers such as LYVE-1 in the infected HDMEC [50].

In our study all LANA+ cells were LYVE-1+ (lymphatic endothelial markers) in early and late KS and the HHV-8 infection (LANA) appeared better correlated to LYVE-1 than to CD34 expression [22]. LANA+/CD34- cells were more frequent in early as compared to late lesions and did not express a leucocytic phenotype (CD3, CD20, CD45, CD68) [21], but most expressed lymphatic endothelial (LEC) markers such as LYVE-1, VEGFR-3 and D2-40, suggesting that resident LECs represent an early target of primary HHV-8 infection [22]. This is also supported by other findings (Wang et al.)[49] that infected LECs have a higher HHV-8 genome copy number than VECs. Obviously a high viral copy number may result in an efficient maintenance and propagation of episomal HHV-8 DNA in dividing and migrating LECs. Furthermore in-vitro activation of VEGFR-3 by HHV-8 has been shown to increase endothelial cell migration and to enhance cell susceptibility to HHV-8 infection and transformation [40]. Hence, the activation of VEGFR-3 in LANA+/VEGFR-3+ SC observed during KS development will probably promote an increased endothelial cell migration

(recruitment) and transformation to tumor SC including formation of pathological vascular slits.

Cell proliferation is relatively low in KS as shown by our previous studies on proliferation related protein Ki67 expression and DNA flow cytometry [27]. The frequency of proliferating (Ki67+) cells usually decreased during development from early to late KS lesions, consistent with the notion that KS growth from a early reactive lesion to a nodular tumor depends not only on SC division but also on decreased apoptosis [27] and progenitor recruitment [21, 22]. No significant difference in cell proliferation was observed between nodular AKS and EKS [21]. These findings could therefore indicate that the usually more spread and aggressive growth of the AKS tumors may reflect a higher rate of SC progenitor recruitment compared to the more indolent EKS lesions.

Cytogenesis of KS

Reports on cytogenetic and molecular genetic changes in KS are few [51]. Studies from KS cell lines, KS Y-1 (AKS derived) and KS SLK (IKS derived) revealed loss of copies of chromosomes 14 and 21 and non-random translocations and deletions in the short arm of chromosome 3 at region 3p14. These KS cell lines also exhibit loss of heterozygosity of loci at region 3p14-ter. The chromosome 3 alterations observed were suggested to contribute to the neoplastic process in KS [52] but other cytogenetic studies on the KS-IMM cell line (IKS) [51] showed gains in 1q10→qter, 7p10→pter, 7q22→qter, 8p11→qter, 14pter→q22 but no changes in chromosome 3 [51]. These aberrations are compatible with the notion that initially KS may develop as a reactive polyclonal cell proliferation associated with chromosome instability, followed by acquisition of clonal chromosome changes in later stages [51]. However, the significance in KS pathogenesis of aberrations on established KS cell lines should be related to finding that such cell lines when established usually lose their HHV-8 episomes and possibly may represent only a minor KS cell population.

The chromosomal instability suggested by the studies on cell lines may lead to cell apoptosis via the p53 pathway [53]. However, HHV-8 LANA binds to p53 repressing its ability to induce apoptosis [54]. Furthermore telomerase activity has been found to be upregulated in KS [55], which may immortalise the infected cell leading to increased tumor cell survival.

Previous, CGH studies of formalin fixed paraffin embedded KS biopsies revealed a recurrent gain at 11q13 [56], which also amplifies two known oncogenes, FGF4 and INT2, residing at

11q13 suggesting a possible role of HHV-8 in the amplification and activation of genomic oncogenes [56].

Loss of chromosome Y was observed in most AKS and EKS cases recently studied by us (64) and interestingly it was the only aberration observed in early KS. Late stage (nodular) KS had beside loss of chromosome Y, also recurrent deletions on chromosomes 16 and 17. Deletion of chromosome Y was also reported by previous studies on short term cultures of primary KS tumor cells and established KS cell lines [51]. EKS showed often more chromosomal abnormalities than AKS (64), which might indicate that genomic instability could be a more important factor in the development of EKS than AKS. Most likely AKS development is also promoted by various cytokines and growth factors produced by the HIV infection and the dysregulated and compromised state of host immune response. Loss of the Y chromosome and encoded male specific minor histocompatibility antigens (HY antigen) has been shown to be linked to haematological relapse in acute lymphoblastic leukemia due to immune escape mechanisms [57]. The HY antigens are presented at the cell surface with the major histocompatibility complex (MHC) and together also processed intracellularly [58]. However, no studies have previously indicated a deficiency of HY antigen in KS tumors, which loss of the Y chromosome in our studies suggests as of possible importance in KS pathogenesis.

HIV-Tat

The increased incidence of KS in patients with AIDS was shown to also be related to effects of the HIV-1 transactivating gene (Tat) protein which stimulates proliferation and inhibits apoptosis of the infected spindle cells and also activates HHV-8 in the infected cell thus increasing viral load and expression of various viral genes with oncogenic potential including vGCR, vBCL2, and vIRF1 [60]. Thus, Tat promotes tumorigenesis of endothelial cells, both via stimulation of vascular endothelial growth factors, anti-apoptotic activity and HHV-8 replication. Notably, the functional activity of Tat protein in the pathogenesis of AKS clearly involves an intercellular signalling cascade which is inhibited by antibodies to HIV-Tat epitopes [61, 62]. This is apparently corroborated by serology studies showing a deficient anti-Tat response of AKS patients compared to HIV-positive non-AKS subjects in HHV-8 endemic area (Tanzania) of Africa [61] suggesting the importance of functional Tat to promote AKS development and aggressiveness[63].

In summary the concept of oncogenesis related to infection is particularly well exemplified by the herpes virus HHV-8 and retrovirus HIV-1 associated Kaposi's sarcoma, which develops

due to the effects of various host-cells and viral factors elicited during infection affecting cell proliferation, cell escape from apoptosis and dysregulation of host immune responses.

Acknowledgements: These studies were supported by Swedish Cancer Society, Cancer Society of Stockholm, Karolinska Institutet research fund and Swedish International Development Agency (Sida), Department of Research Cooperation (SAREC).

Drs. L. Lema, and B. Kalyanyama of the Muhimbili University College, Drs. J. Luande, T. Ngoma, M. Diwani of Ocean Road Cancer Institute (ORCI), Dar-Es-Salaam, Tanzania provided the biopsies. The technical assistance of A. Magogo and V. Nelson from Muhimbili University College, Dar-Es-Salaam, Tanzania is highly appreciated.

The ethical clearance was obtained from Ministry of Health (MoH), and the Muhimbili University College of Health Sciences (MUCHS) in Dar Es Salaam, Tanzania and The ethical committee, Karolinska Hospital (Dnr 01-096). We declare no conflict of interest.

References

1. Kaposi M. Idiopathisches multiples pigment sarcoma de Haut. *Arch Dermatol Syphil* 1872; 4.
2. Biberfeld P, Ensoli B, Sturzl M, Schulz TF. Kaposi sarcoma-associated herpesvirus/human herpesvirus 8, cytokines, growth factors and HIV in pathogenesis of Kaposi's sarcoma. *Curr Opin Infect Dis* 1998; 11:97-105.
3. Amir H, Kaaya EE, Manji KP, Kwesigabo G, Biberfeld P. Kaposi's sarcoma before and during a human immunodeficiency virus epidemic in Tanzanian children. *Pediatr Infect Dis J* 2001; 20:518-521.
4. Lessan-Pezeshki M, Einollahi B, Khatami MR, Mahdavi M. Kidney transplantation and Kaposi's sarcoma: review of 2050 recipients. *Transplant Proc* 2001; 33:2818.
5. Biberfeld P, Lebbe C, Tschachler E, Luppi M. Human herpesvirus-8 and HIV. In: Viral co-infections in HIV Impact and management. In: *Lalezari J, Moyle G: Remedica*; 2002:63-91.
6. Kaaya EE, Parravicini C, Sundelin B, Mgaya E, Kitinya J, Lema L, *et al.* Spindle cell ploidy and proliferation in endemic and epidemic African Kaposi's sarcoma. *Eur J Cancer* 1992; 28A:1890-1894.
7. Chang Y, Cesarman E, Pessin MS, Lee F, Culpepper J, Knowles DM, *et al.* Identification of herpesvirus-like DNA sequences in AIDS-associated Kaposi's sarcoma. *Science* 1994; 266:1865-1869.
8. Schalling M, Ekman M, Kaaya EE, Linde A, Biberfeld P. A role for a new herpes virus (KSHV) in different forms of Kaposi's sarcoma. *Nat Med* 1995; 1:707-708.
9. Gaidano G, Castanos-Velez E, Biberfeld P. Lymphoid disorders associated with HHV-8/KSHV infection: facts and contentions. *Med Oncol* 1999; 16:8-12.
10. Viejo-Borbolla A, Ottinger M, Schulz TF. Human Herpesvirus 8: Biology and Role in the Pathogenesis of Kaposi's Sarcoma and Other AIDS-related Malignancies. *Curr Infect Dis Rep* 2003; 5:169-175.
11. Wang FZ, Akula SM, Pramod NP, Zeng L, Chandran B. Human herpesvirus 8 envelope glycoprotein K8.1A interaction with the target cells involves heparan sulfate. *J Virol* 2001; 75:7517-7527.
12. Akula SM, Naranatt PP, Walia NS, Wang FZ, Fegley B, Chandran B. Kaposi's sarcoma-associated herpesvirus (human herpesvirus 8) infection of human fibroblast cells occurs through endocytosis. *J Virol* 2003; 77:7978-7990.
13. Hengge UR, Ruzicka T, Tyring SK, Stuschke M, Roggendorf M, Schwartz RA, *et al.* Update on Kaposi's sarcoma and other HHV8 associated diseases. Part 2: pathogenesis, Castleman's disease, and pleural effusion lymphoma. *Lancet Infect Dis* 2002; 2:344-352.
14. Renne R, Lagunoff M, Zhong W, Ganem D. The size and conformation of Kaposi's sarcoma-associated herpesvirus (human herpesvirus 8) DNA in infected cells and virions. *J Virol* 1996; 70:8151-8154.
15. Schulz TF. Kaposi's sarcoma-associated herpesvirus (human herpesvirus 8): epidemiology and pathogenesis. *J Antimicrob Chemother* 2000; 45 Suppl T3:15-27.
16. Szekely L, Kiss C, Mattsson K, Kashuba E, Pokrovskaja K, Juhasz A, *et al.* Human herpesvirus-8-encoded LNA-1 accumulates in heterochromatin-associated nuclear bodies. *J Gen Virol* 1999; 80 (Pt 11):2889-2900.
17. Komatsu T, Ballestas ME, Barbera AJ, Kaye KM. The KSHV latency-associated nuclear antigen: a multifunctional protein. *Front Biosci* 2002; 7:d726-730.

18. Radkov SA, Kellam P, Boshoff C. The latent nuclear antigen of Kaposi sarcoma-associated herpesvirus targets the retinoblastoma-E2F pathway and with the oncogene Hras transforms primary rat cells. *Nat Med* 2000; 6:1121-1127.
19. Jenner RG, Boshoff C. The molecular pathology of Kaposi's sarcoma-associated herpesvirus. *Biochim Biophys Acta* 2002; 1602:1-22.
20. Katano H, Sato Y, Kurata T, Mori S, Sata T. High expression of HHV-8-encoded ORF73 protein in spindle-shaped cells of Kaposi's sarcoma. *Am J Pathol* 1999; 155:47-52.
21. Pyakurel P, Massambu C, Castanos-Velez E, Ericsson S, Kaaya E, Biberfeld P, *et al.* Human Herpesvirus 8/Kaposi Sarcoma Herpesvirus Cell Association During Evolution of Kaposi Sarcoma. *J Acquir Immune Defic Syndr* 2004; 36:678-683.
22. Pyakurel P, Pak F, Mwakigonja AR, Kaaya E, Heiden T, Biberfeld P. Lymphatic and vascular origin of Kaposi's sarcoma spindle cells during tumor development. *Int J Cancer* 2006.
23. Biberfeld P EB, Sturzl M, and Schulz TF. Kaposi's sarcoma associated herpesvirus/human herpesvirus 8, cytokine growth factors and HIV in pathogenesis of Kaposi's sarcoma. *Curr Opin Inf Dis* 1998; 11:105.
24. Dalgleish AG, O'Byrne KJ. Chronic immune activation and inflammation in the pathogenesis of AIDS and cancer. *Adv Cancer Res* 2002; 84:231-276.
25. Moore PS, Chang Y. Kaposi's sarcoma-associated herpesvirus immunoevasion and tumorigenesis: two sides of the same coin? *Annu Rev Microbiol* 2003; 57:609-639.
26. Belanger C, Gravel A, Tomoiu A, Janelle ME, Gosselin J, Tremblay MJ, *et al.* Human herpesvirus 8 viral FLICE-inhibitory protein inhibits Fas-mediated apoptosis through binding and prevention of procaspase-8 maturation. *J Hum Virol* 2001; 4:62-73.
27. Kaaya E, Castanos-Velez E, Heiden T, Ekman M, Catrina AI, Kitinya J, *et al.* Proliferation and apoptosis in the evolution of endemic and acquired immunodeficiency syndrome-related Kaposi's sarcoma. *Med Oncol* 2000; 17:325-332.
28. Sturzl M, Hohenadl C, Zietz C, Castanos-Velez E, Wunderlich A, Ascherl G, *et al.* Expression of K13/v-FLIP gene of human herpesvirus 8 and apoptosis in Kaposi's sarcoma spindle cells. *J Natl Cancer Inst* 1999; 91:1725-1733.
29. Verma SC, Robertson ES. Molecular biology and pathogenesis of Kaposi sarcoma-associated herpesvirus. *FEMS Microbiol Lett* 2003; 222:155-163.
30. Muralidhar S, Pumfery AM, Hassani M, Sadaie MR, Kishishita M, Brady JN, *et al.* Identification of kaposin (open reading frame K12) as a human herpesvirus 8 (Kaposi's sarcoma-associated herpesvirus) transforming gene. *J Virol* 1998; 72:4980-4988.
31. Direkze S, Laman H. Regulation of growth signalling and cell cycle by Kaposi's sarcoma-associated herpesvirus genes. *Int J Exp Pathol* 2004; 85:305-319.
32. Sadler R, Wu L, Forghani B, Renne R, Zhong W, Herndier B, *et al.* A complex translational program generates multiple novel proteins from the latently expressed kaposin (K12) locus of Kaposi's sarcoma-associated herpesvirus. *J Virol* 1999; 73:5722-5730.
33. McCormick C, Ganem D. The kaposin B protein of KSHV activates the p38/MK2 pathway and stabilizes cytokine mRNAs. *Science* 2005; 307:739-741.
34. Pfeffer S, Sewer A, Lagos-Quintana M, Sheridan R, Sander C, Grasser FA, *et al.* Identification of microRNAs of the herpesvirus family. *Nat Methods* 2005; 2:269-276.
35. Sturzl M, Blasig C, Schreier A, Neipel F, Hohenadl C, Cornali E, *et al.* Expression of HHV-8 latency-associated T0.7 RNA in spindle cells and endothelial cells of AIDS-associated, classical and African Kaposi's sarcoma. *Int J Cancer* 1997; 72:68-71.

36. Yen-Moore A, Hudnall SD, Rady PL, Wagner RF, Jr., Moore TO, Memar O, *et al.* Differential expression of the HHV-8 vGCR cellular homolog gene in AIDS-associated and classic Kaposi's sarcoma: potential role of HIV-1 Tat. *Virology* 2000; 267:247-251.
37. Cannon M, Philpott NJ, Cesarman E. The Kaposi's sarcoma-associated herpesvirus G protein-coupled receptor has broad signaling effects in primary effusion lymphoma cells. *J Virol* 2003; 77:57-67.
38. Choi J, Means RE, Damania B, Jung JU. Molecular piracy of Kaposi's sarcoma associated herpesvirus. *Cytokine Growth Factor Rev* 2001; 12:245-257.
39. Samaniego F, Markham PD, Gendelman R, Watanabe Y, Kao V, Kowalski K, *et al.* Vascular endothelial growth factor and basic fibroblast growth factor present in Kaposi's sarcoma (KS) are induced by inflammatory cytokines and synergize to promote vascular permeability and KS lesion development. *Am J Pathol* 1998; 152:1433-1443.
40. Zhang X, Wang JF, Chandran B, Persaud K, Pytowski B, Fingerroth J, *et al.* KSHV activation of VEGFR-3 alters endothelial function and enhances infection. *J Biol Chem* 2005.
41. Kondo Y, Izumi T, Yanagawa T, Kanda H, Katano H, Sata T. Spontaneously regressed Kaposi's sarcoma and human herpesvirus 8 infection in a human immunodeficiency virus-negative patient. *Pathol Int* 2000; 50:340-346.
42. Ensoli B, Sgadari C, Barillari G, Sirianni MC, Sturzl M, Monini P. Biology of Kaposi's sarcoma. *Eur J Cancer* 2001; 37:1251-1269.
43. Browning PJ, Sechler JM, Kaplan M, Washington RH, Gendelman R, Yarchoan R, *et al.* Identification and culture of Kaposi's sarcoma-like spindle cells from the peripheral blood of human immunodeficiency virus-1-infected individuals and normal controls. *Blood* 1994; 84:2711-2720.
44. Barozzi P, Luppi M, Facchetti F, Mecucci C, Alu M, Sarid R, *et al.* Post-transplant Kaposi sarcoma originates from the seeding of donor-derived progenitors. *Nat Med* 2003; 9:554-561.
45. Carroll PA, Brazeau E, Lagunoff M. Kaposi's sarcoma-associated herpesvirus infection of blood endothelial cells induces lymphatic differentiation. *Virology* 2004; 328:7-18.
46. Jussila L, Valtola R, Partanen TA, Salven P, Heikkila P, Matikainen MT, *et al.* Lymphatic endothelium and Kaposi's sarcoma spindle cells detected by antibodies against the vascular endothelial growth factor receptor-3. *Cancer Res* 1998; 58:1599-1604.
47. Masood R, Xia G, Smith DL, Scalia P, Still JG, Tulpule A, *et al.* Ephrin B2 expression in Kaposi's sarcoma is induced by human herpes virus type 8: phenotype switch from venous to arterial endothelium. *Blood* 2004.
48. Kahn HJ, Bailey D, Marks A. Monoclonal antibody D2-40, a new marker of lymphatic endothelium, reacts with Kaposi's sarcoma and a subset of angiosarcomas. *Mod Pathol* 2002; 15:434-440.
49. Wang HW, Trotter MW, Lagos D, Bourboulia D, Henderson S, Makinen T, *et al.* Kaposi sarcoma herpesvirus-induced cellular reprogramming contributes to the lymphatic endothelial gene expression in Kaposi sarcoma. *Nat Genet* 2004; 36:687-693.
50. Hong YK, Foreman K, Shin JW, Hirakawa S, Curry CL, Sage DR, *et al.* Lymphatic reprogramming of blood vascular endothelium by Kaposi sarcoma-associated herpesvirus. *Nat Genet* 2004; 36:683-685.

51. Casalone R, Albin A, Righi R, Granata P, Toniolo A. Nonrandom chromosome changes in Kaposi sarcoma: cytogenetic and FISH results in a new cell line (KS-IMM) and literature review. *Cancer Genet Cytogenet* 2001; 124:16-19.
52. Popescu NC, Zimonjic DB, Leventon-Kriss S, Bryant JL, Lunardi-Iskandar Y, Gallo RC. Deletion and translocation involving chromosome 3 (p14) in two tumorigenic Kaposi's sarcoma cell lines. *J Natl Cancer Inst* 1996; 88:450-455.
53. Artandi SE, Attardi LD. Pathways connecting telomeres and p53 in senescence, apoptosis, and cancer. *Biochem Biophys Res Commun* 2005; 331:881-890.
54. Friborg J, Jr., Kong W, Hottiger MO, Nabel GJ. p53 inhibition by the LANA protein of KSHV protects against cell death. *Nature* 1999; 402:889-894.
55. Chen Z, Smith KJ, Skelton HG, 3rd, Barrett TL, Greenway HT, Jr., Lo SC. Telomerase activity in Kaposi's sarcoma, squamous cell carcinoma, and basal cell carcinoma. *Exp Biol Med (Maywood)* 2001; 226:753-757.
56. Kiuru-Kuhlefelt S, Sarlomo-Rikala M, Larramendy ML, Soderlund M, Hedman K, Miettinen M, et al. FGF4 and INT2 oncogenes are amplified and expressed in Kaposi's sarcoma. *Mod Pathol* 2000; 13:433-437.
57. Wolff D, Knopp A, Weirich V, Steiner B, Junghanss C, Casper J, et al. Loss of the GVL effect by loss of the Y-chromosome as putative mechanism of immune escape in ALL. *Bone Marrow Transplant* 2005; 35:101-102.
58. Rotzschke O, Falk K, Wallny HJ, Faath S, Rammensee HG. Characterization of naturally occurring minor histocompatibility peptides including H-4 and H-Y. *Science* 1990; 249:283-287.
59. Ensoli B, Gendelman R, Markham P, Fiorelli V, Colombini S, Raffeld M, et al. Synergy between basic fibroblast growth factor and HIV-1 Tat protein in induction of Kaposi's sarcoma. *Nature* 1994; 371:674-680.
60. Harrington W, Jr., Sieczkowski L, Sosa C, Chan-a-Sue S, Cai JP, Cabral L, et al. Activation of HHV-8 by HIV-1 tat. *Lancet* 1997; 349:774-775.
61. Demirhan I, Chandra A, Hasselmayer O, Biberfeld P, Chandra P. Detection of distinct patterns of anti-tat antibodies in HIV-infected individuals with or without Kaposi's sarcoma. *J Acquir Immune Defic Syndr* 1999; 22:364-368.
62. Demirhan I, Chandra A, Hasselmayer O, Chandra P. Intercellular traffic of human immunodeficiency virus type 1 transactivator protein defined by monoclonal antibodies. *FEBS Lett* 1999; 445:53-56.
63. Ensoli B, Sturzl M. Kaposi's sarcoma: a result of the interplay among inflammatory cytokines, angiogenic factors and viral agents. *Cytokine Growth Factor Rev* 1998; 9:63-83.
64. Pyakurel P, Montag U, Castaños-Vélez E, Kaaya E, Christensson B, Tönnies H, Biberfeld P, Heiden T. CGH of microdissected Kaposi's sarcoma lesions reveals recurrent loss of chromosome Y in early and additional chromosomal changes in late tumor stages. *AIDS* 2006; 20(14):1805-12

Figure Legend

Fig 1. *HHV-8 gene expression(pathogenesis) during SC development and tumor growth.*

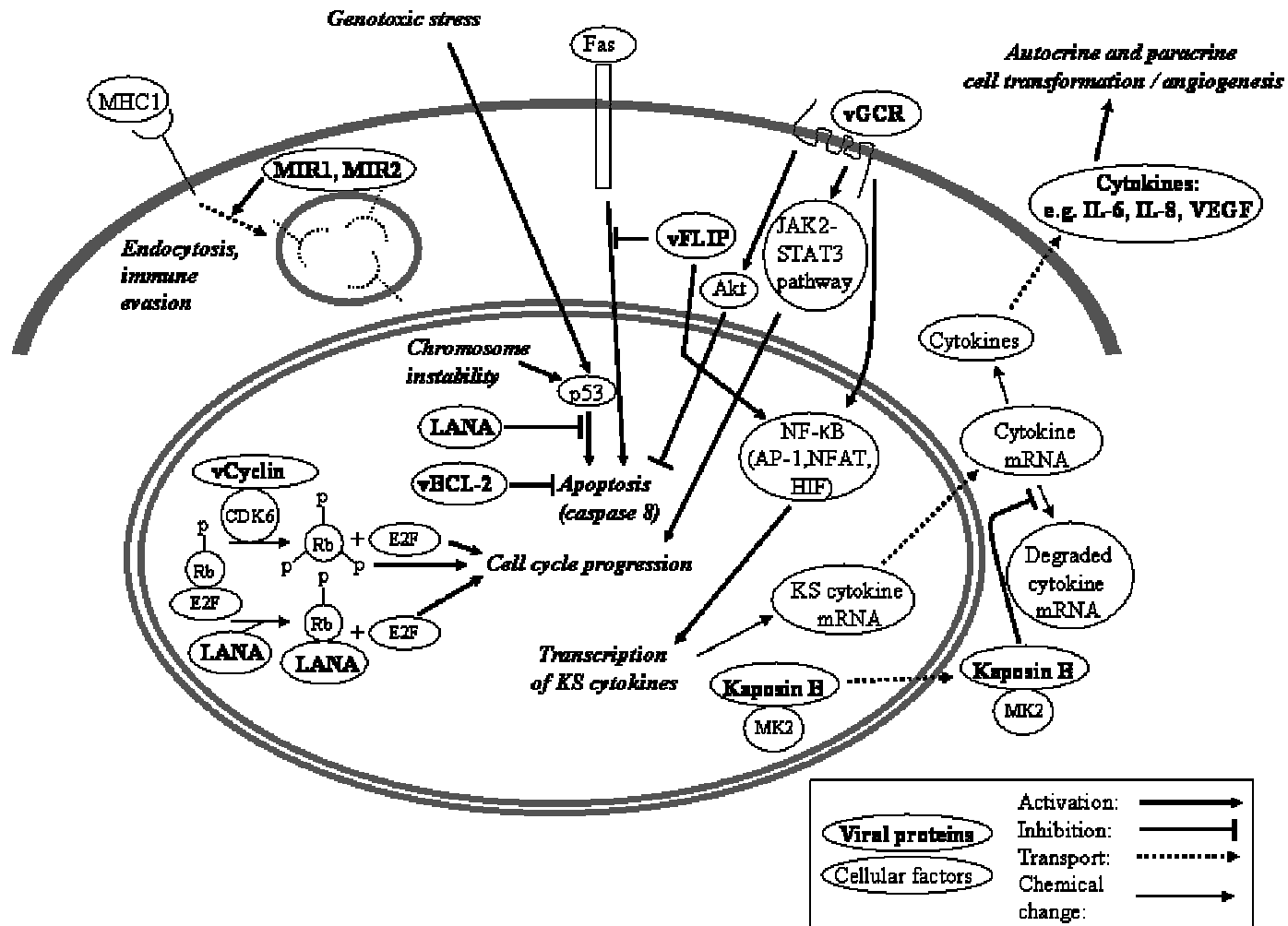


Fig 1